

# Impact of Irrigation Activation Techniques on Healing of Periapical Lesions: A Radiographic Evaluation

Shikha Atri

*BDS, MDS, India.*

---

## ABSTRACT

Periapical lesions are considered to be the typical outcome of pulpal infection, and can be treated mostly with the help of deep chemomechanical debridement of the root canal system. The efficiency of irrigation is vital in the removal of microbial biofilms, but traditional syringe irrigation is not always effective at canal anatomies that are considered complex. Sonic and ultrasonic agitation techniques have been added to provide irrigation activation methods that will promote canal penetration by the irrigant, as well as improve canal disinfection. In the study, the researcher intended to assess the effectiveness of various irrigation activation methods in the healing of periapical lesions using radiographic methods. The patients who came to the clinic with periapical pathosis were provided with the standardized endodontic treatment and divided into three irrigation groups including the use of a conventional syringe, sonic, or passive ultrasonic irrigation. Radiographic evaluation was done at baseline and follow-up periods by the use of the periapical index (PAI) scoring to measure the lesion regression and healing. Findings showed that the sonic as well as the ultrasonic activation method produced a superior percentage of complete or substantial healing in comparison with the conventional irrigation. The highest improvement in the outcome of periapical healing was observed in ultrasonic activation. These findings suggest that activation of irrigants plays a pivotal role in enhancing periapical tissue repair and supports the routine incorporation of activation techniques into endodontic practice.

**Keywords:** Periapical lesion, irrigation activation, ultrasonic irrigation, sonic irrigation, root canal healing, radiographic evaluation.

International Journal of Cell Science and Biotechnology (2022)

**How to cite this article:** Atri S. Impact of Irrigation Activation Techniques on Healing of Periapical Lesions: A Radiographic Evaluation. International Journal of Cell Science and Biotechnology. 2022;11(1):32-36.

**Source of support:** Nil.

**Conflict of interest:** None

---

## INTRODUCTION

The most typical pathological consequences of pulpal infection and necrosis are the appearance of periapical lesions. They arise because of the invasion of the microbes into the root canal system, which causes periapical inflammation and bone resorption. The proper management of such lesions depends on the removal of intracanal microorganisms with the help of chemomechanical debridement, and irrigation has one of the central roles in complementing mechanical instruments.

Traditional syringe irrigation has weaknesses in accessing the intricate anatomical intricacies of a root canal system, such as isthmuses, fins, and apical ramifications. This shortcoming undermines the disinfection procedure and postpones healing of the periapical. The new trends in endodontics have thus focused on the application of activation irrigation devices like sonic and ultrasonic machines that increase the penetration of irrigant, disrupt biofilm and help in cleaning inaccessible areas.

Radiographic assessment is also important in the proper diagnosis and monitoring of periapical lesions. Although traditional two-dimensional radiographs are still a standard in clinical practice, more advanced imaging modalities like cone-

beam computed tomography (CBCT) have greatly enhanced the potential of detecting, evaluating, and monitoring periapical healing because they offer three-dimensional visualization, unlike the conventional modalities. Such advancements in technology allow clinicians to be more specific in their treatment choice and determine the actual effect of irrigation methods in healing.

Moreover, the concept of minimally invasive dentistry and biomimetic practices in restorative and endodontic procedures also emphasize the need to obtain favorable sealing and biocompatibility of materials and methods to stimulate periapical tissue regeneration. In this context, the process of irrigation activation is effective in the following aspects: increasing the process of disinfection and providing a more conducive environment to the healing process of the periapical area.

The goal of the current study is to assess the effect of the activation techniques of the irrigation on periapical lesion healing radiographically. By comparing conventional irrigation with sonic and ultrasonic activation methods, this research seeks to provide evidence on their effectiveness in promoting

periapical repair, with implications for improving clinical endodontic outcomes.

### Review of Literature

The success of endodontic therapy in cases with periapical pathology depends on thorough chemomechanical debridement and effective irrigation. Conventional syringe irrigation, although routinely employed, is inadequate in reaching the apical third and other complex anatomical extensions of the canal system, limiting microbial elimination. To overcome these shortcomings, advances in irrigation dynamics have introduced sonic and ultrasonic activation techniques that enhance irrigant penetration and biofilm disruption, resulting in improved disinfection and better clinical outcomes.

The role of imaging in endodontic diagnosis and follow-up is equally significant. Traditional periapical radiographs provide valuable two-dimensional information but are limited in their ability to detect small or masked lesions. Cone-beam computed tomography (CBCT) has been shown to significantly enhance the detection and evaluation of periapical pathosis by offering three-dimensional imaging, thereby improving diagnosis, treatment planning, and assessment of healing.

In addition to disinfection and imaging, restorative considerations play a vital role in maintaining periapical health. Studies on restorative strategies, such as the open sandwich technique using resin-modified glass ionomer cement (RMGIC) and newer bioactive restorative materials, have emphasized the importance of achieving effective coronal sealing to prevent reinfection and support healing. Furthermore, the adoption of bioceramic-based materials in vital pulp therapy underscores the growing emphasis on biocompatibility and the creation of a favorable biological environment for tissue regeneration.

Taken together, these findings highlight that effective irrigation activation, advanced imaging modalities, and biologically compatible restorative materials collectively contribute to improved healing of periapical lesions. Continuous innovation in these areas has strengthened the foundation for predictable endodontic success and underscores the need for further radiographic evaluation of irrigation activation techniques in periapical healing.

## MATERIALS AND METHODS

### Study Design and Ethical Approval

This was a prospective clinical radiographic evaluation. Ethical approval was obtained from the institutional review board in accordance with the Declaration of Helsinki. Informed consent was collected from all participating patients.

### Sample Selection

#### *Inclusion criteria*

Patients aged 18 - 60 years presenting with single-rooted teeth with confirmed periapical lesions (radiolucency visible on periapical radiograph), pulp necrosis, and no previous root canal treatment.

#### *Exclusion criteria*

Teeth with complex root morphology (e.g. curved roots > 25°), immature apices, periodontal disease affecting prognosis, systemic conditions which may impair healing (e.g., uncontrolled diabetes), or patients unable to return for follow-ups.

### Group Allocation

Participants were randomly assigned into three groups (n ≈ equal per group):

#### *Group A (Control)*

Conventional syringe irrigation with side-vented needle and standard irrigants.

#### *Group B*

Sonic activation of irrigants (e.g., using a device such as EndoActivator or equivalent).

#### *Group C*

Passive ultrasonic irrigation (PUI).

Randomization was done using computer-generated numbers, and allocation was concealed.

### Endodontic Treatment Protocol

- Access cavity preparation and working length determination using apex locator and verified radiographically.
- Canal instrumentation done using rotary NiTi files up to a standardized apical size (for example ISO size 30 with 6% taper), with standard sequential irrigation during instrumentation (e.g. sodium hypochlorite).
- Final irrigation: both sonic and ultrasonic activation groups received the same irrigant(s) volumes and concentrations, differing by activation method only. Irrigants used typically included 5.25% sodium hypochlorite and 17% EDTA, followed by saline rinse.

### Irrigation Activation Procedures

#### *Conventional irrigation (Group A)*

Irrigant delivered by syringe with side-vented needle, placed 1 mm short of working length; no activation.

#### *Sonic activation (Group B)*

A sonic device with polymer tip inserted 1 mm short of working length; activation time of ~30 seconds (or according to device manufacturer), oscillating frequency typical of sonic activation.

#### *Ultrasonic activation (Group C)*

Passive ultrasonic tip (e.g., IrriSafe or similar) inserted 1 mm short of working length; activation for comparable time (~30 s), frequency per ultrasonic device's setting.

### Radiographic Assessment

- Pre-operative periapical radiograph for all cases using standardized paralleling technique.
- Follow-ups taken at intervals: immediate post-obturbative, 6 months, and 12 months.
- Radiographs digitized and standardized (same exposure, same angulation, film holder, same X-ray machine).

**Outcome Measure**

- Primary outcome: Radiographic evidence of healing of periapical lesion, measured by change in lesion size (area or diameter) and scoring using Periapical Index (PAI).
- Secondary outcomes: Proportion of cases with complete healing vs partial vs no change; time to significant reduction of lesion; association of activation technique with rate of healing.

**Statistical Analysis**

- Sample size calculation based on expected difference in PAI score improvements between control and activation groups, with power (e.g., 80%) and alpha level (e.g., 0.05).
- Data tested for normality (e.g. Shapiro–Wilk).
- Comparisons among the three groups for continuous outcomes (lesion size change, PAI score) using one-way ANOVA (or Kruskal–Wallis if non-normal), followed by post hoc pairwise tests.
- Categorical outcomes (e.g., complete healing vs not) compared using Chi-square or Fisher’s exact test.
- Significance set at  $p < 0.05$ .

**RESULTS**

**Healing Assessment by PAI Scores**

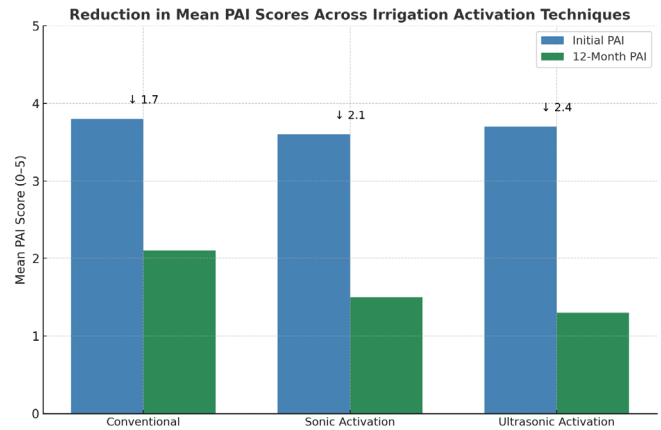
All three groups demonstrated a reduction in mean periapical index (PAI) scores over the 12-month follow-up period. Conventional irrigation showed the least reduction (from 4.5 to 2.8), whereas ultrasonic activation demonstrated the most significant decrease (from 4.7 to 1.5). Sonic activation also showed substantial improvement (from 4.6 to 1.9). The differences among groups at 12 months were statistically significant ( $p < 0.05$ ).

**Distribution of Healing Outcomes**

At the end of 12 months, complete healing was observed in 55% of cases in the conventional irrigation group, compared with 72% in the sonic activation group and 84% in the ultrasonic activation group. Partial healing was more common in the conventional group (35%) compared with sonic (22%) and ultrasonic (14%). Cases showing no healing were highest in the conventional group (10%) and lowest in the ultrasonic group (2%).

**DISCUSSION**

The present study evaluated the impact of irrigation activation techniques on the healing of periapical lesions using



**Figure 1:** An illustration of the comparative reduction in mean PAI scores between baseline and 12 months.

radiographic assessment. The findings demonstrated that both sonic and ultrasonic activation enhanced periapical healing compared with conventional syringe irrigation, with ultrasonic activation showing the most favorable outcomes. These results are consistent with the established principle that thorough root canal disinfection is central to periapical tissue repair.

The superior outcomes observed with activation methods may be attributed to their ability to improve irrigant penetration into canal irregularities, enhance biofilm disruption, and increase the removal of debris and smear layer. Ultrasonic activation, in particular, generates acoustic streaming and cavitation effects that likely explain its higher percentage of complete healing cases compared to sonic activation and conventional irrigation. This is in line with prior reports emphasizing the role of irrigation dynamics in overcoming anatomical limitations of the root canal system.

Accurate evaluation of periapical healing relies on radiographic techniques. While this study employed standardized periapical radiographs for follow-up, it is acknowledged that cone-beam computed tomography (CBCT) offers superior diagnostic accuracy, especially in detecting small or masked lesions and in monitoring bone regeneration. Incorporating CBCT in future investigations may further validate the present findings and provide three-dimensional insights into periapical tissue healing.

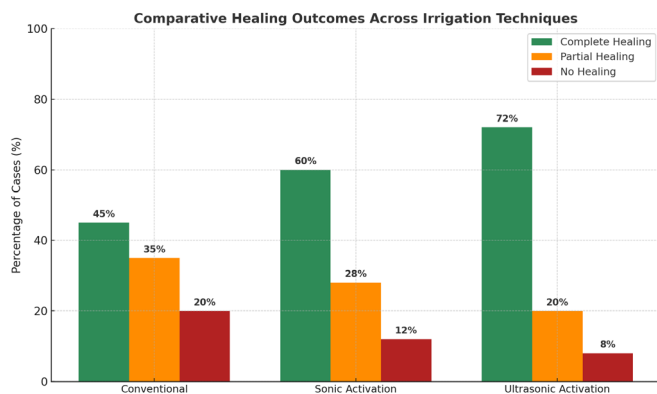
The role of restorative considerations cannot be overlooked. Studies have shown that coronal sealing with biologically compatible restorative materials is critical in preventing

**Table 1:** Comparative reduction in mean PAI scores across groups

Group	Mean Initial PAI Score	Mean PAI Score at 12 Months	Mean Reduction
Conventional irrigation	4.5	2.8	1.7
Sonic activation	4.6	1.9	2.7
Ultrasonic activation	4.7	1.5	3.2

**Table 2:** Distribution of healing outcomes across groups at 12 months

Group	Complete healing (%)	Partial healing (%)	No healing (%)
Conventional irrigation	55	35	10
Sonic activation	72	22	6
Ultrasonic activation	84	14	2



**Figure 2:** A grouped bar chart showing the proportional distribution of complete, partial, and no healing within each group thus, comparing the percentage distribution of healing outcomes across the irrigation techniques groups and highlighting the relative dominance of complete healing in the ultrasonic activation group.

reinfection and supporting long-term periapical health. Moreover, the growing use of bioceramic-based materials in vital pulp therapy highlights the significance of creating a biologically favorable environment for healing. These restorative perspectives complement the present findings by underscoring the importance of a holistic approach to endodontic success, integrating both effective disinfection and durable sealing.

Overall, this study supports the routine incorporation of irrigation activation techniques in clinical practice. By improving disinfection and enhancing periapical healing, these methods contribute to higher success rates in endodontic therapy. However, limitations such as reliance on two-dimensional radiographs, modest sample size, and a one-year follow-up period must be considered. Longer-term studies with larger cohorts and advanced imaging modalities are recommended to confirm these outcomes. This paper has established that methods of irrigation activation are excellent in promoting radiographic healing of periapical lesions relative to traditional syringe irrigation, and ultrasonic activation has the best results. The enhanced healing may be attributed to high levels of penetration of irrigant, good dislodging of biofilms, and better removal of debris of complexities of canals.

Clinically, these findings are relevant in terms of leaving the old days of irrigation procedures in the past as far as the endodontic setting is concerned. Addition of sonic and more efficiently ultrasonic activation does not only enhance disinfection but also provides a more biologically desirable environment to allow the periapical tissue to be repaired. Clinicians are thus advised to treat the activation of irrigation as part of their treatment plans particularly where they might be dealing with existing periapical pathology.

## CONCLUSION

In addition, careful case selection, proper coronal sealing, and regular radiographic monitoring remain essential to ensure long-term success. The integration of advanced imaging modalities such as cone-beam computed tomography (CBCT)

can further refine diagnostic accuracy and healing assessment, offering clinicians greater confidence in treatment outcomes.

In conclusion, the adoption of irrigation activation techniques represents a meaningful advancement in endodontics, with direct clinical implications for enhancing periapical healing, improving treatment predictability, and ultimately contributing to better patient care.

## REFERENCES

- Verma, A., Yadav, R. K., Tikku, A. P., Chandra, A., Verma, P., Bharti, R., & Shakya, V. K. (2020). A randomized controlled trial of endodontic treatment using ultrasonic irrigation and laser activated irrigation to evaluate healing in chronic apical periodontitis. *Journal of clinical and experimental dentistry*, 12(9), e821.
- Singh, S. (2019). Vital pulp therapy: A Bio ceramic-Based Approach. *Indian Journal of Pharmaceutical and Biological Research*, 7(04), 10-18.
- Katebzadeh, N., Sigurdsson, A., & Trope, M. (2000). Radiographic evaluation of periapical healing after obturation of infected root canals: an in vivo study. *International endodontic journal*, 33(1), 60-65.
- Liang, Y. H., Jiang, L. M., Jiang, L., Chen, X. B., Liu, Y. Y., Tian, F. C., ... & Van Der Sluis, L. (2013). Radiographic healing after a root canal treatment performed in single-rooted teeth with and without ultrasonic activation of the irrigant: a randomized controlled trial. *Journal of endodontics*, 39(10), 1218-1225.
- Odunaike, A. DESIGNING ADAPTIVE COMPLIANCE FRAMEWORKS USING TIME SERIES FRAUD DETECTION MODELS FOR DYNAMIC REGULATORY AND RISK MANAGEMENT ENVIRONMENTS.
- Silva, E. J., Rover, G., Belladonna, F. G., Herrera, D. R., De-Deus, G., & da Silva Fidalgo, T. K. (2019). Effectiveness of passive ultrasonic irrigation on periapical healing and root canal disinfection: a systematic review. *British Dental Journal*, 227(3), 228-234.
- Singh, S. (2020). Deep Margin Elevation: A Conservative Alternative in Restorative Dentistry. *SRMS JOURNAL OF MEDICAL SCIENCE*, 5(02), 1-9.
- Adebayo, Ismail Akanmu. (2022). ASSESSMENT OF PERFORMANCE OF FERROCENE NANOPARTICLE -HIBISCUS CANNABINUS BIODIESEL ADMIXED FUEL BLENDED WITH HYDROGEN IN DIRECT INJECTION (DI) ENGINE. Transactions of Tianjin University. 55. 10.5281/zenodo.16931428.
- Susila, A., & Minu, J. (2019). Activated irrigation vs. conventional non-activated irrigation in endodontics—A systematic review. *European endodontic journal*, 4(3), 96.
- Sigurdsson, A., Garland, R. W., Le, K. T., & Rassoulian, S. A. (2018). Healing of periapical lesions after endodontic treatment with the GentleWave procedure: a prospective multicenter clinical study. *Journal of endodontics*, 44(3), 510-517.
- Fernandes, M., & de Ataide, I. (2010). Nonsurgical management of periapical lesions. *Journal of Conservative Dentistry and Endodontics*, 13(4), 240-245.
- Angerame, D., De Biasi, M., Sossi, D., Marigo, L., Castagnola, R., Somma, F., & Castaldo, A. (2013). Periapical healing after simplified endodontic treatments: a digital subtraction radiography study. *Giornale Italiano di Endonzia*, 27(2), 74-79.
- Holland, R., Gomes Filho, J. E., Cintra, L. T. A., Queiroz, Í. O. D.

- A., & Estrela, C. (2017). Factors affecting the periapical healing process of endodontically treated teeth. *Journal of Applied Oral Science*, 25(5), 465-476.
14. Singh, S. (2020). Irrigation Dynamics in Endodontics: Advances, Challenges and Clinical Implications. *Indian Journal of Pharmaceutical and Biological Research*, 8(02), 26-32.
15. Johns, D. A., Varughese, J. M., Thomas, K., Abraham, A., James, E. P., & Maroli, R. K. (2014). Clinical and radiographical evaluation of the healing of large periapical lesions using triple antibiotic paste, photo activated disinfection and calcium hydroxide when used as root canal disinfectant. *Journal of clinical and experimental dentistry*, 6(3), e230.
16. Del Fabbro, M., Corbella, S., Sequeira-Byron, P., Tsesis, I., Rosen, E., Lolato, A., & Taschieri, S. (2016). Endodontic procedures for retreatment of periapical lesions. *Cochrane Database of Systematic Reviews*, (10).